

## Original Research Article

# IMPEDANCE AUDIOMETRY FINDINGS AMONG CHILDREN WITH ADENOID HYPERTROPHY

Deepti Singh<sup>1</sup>, Kapil Singh<sup>2</sup>, Shilpi Sujata<sup>3</sup>, Vaibhav Shahi<sup>4</sup>

<sup>1</sup>Assistant Professor, Department of ENT, LLRM Medical College, Meerut, India.

<sup>2</sup>Associate Professor, Department of ENT, LLRM Medical College, Meerut, India.

<sup>3</sup>Senior Resident, Department of ENT, LLRM Medical College, Meerut, India.

<sup>4</sup>Junior Resident, Department of ENT, LLRM Medical College, Meerut, India.

Received : 07/11/2024  
Received in revised form : 29/11/2024  
Accepted : 08/12/2024

**Corresponding Author:**

**Dr. Vaibhav Shahi,**  
Junior Resident, Department of ENT,  
LLRM Medical College, Meerut, India.  
Email: vaibhavshahi212121@gmail.com

DOI:10.70034/ijmedph.2024.4.248

Source of Support: Nil,  
Conflict of Interest: None declared

**Int J Med Pub Health**  
2024; 14 (4); 1355-1358

**ABSTRACT**

**Background:** The upper aero-digestive tract's initial line of defense includes adenoid tissue. It is situated behind the choana in the nasopharynx's postero-superior wall. The pathophysiology of otitis media with effusion (OME), the primary cause of hearing impairment in young children, is greatly influenced by adenoid hypertrophy, a common childhood condition.

**Material and Methods:** A prospective control study was conducted on 131 newly diagnosed cases of adenoid hypertrophy. Each child with adenoid hypertrophy had an audiometric evaluation, and each case was treated as a separate entity. otitis media with effusion was detected using Types B and C.

**Results:** The incidence of type B tympanograms was 29.77% and type C tympanograms were 25.95%. 56.1% of people had Otitis Media with effusion. Patients with grade 3 adenoid hypertrophy appeared to be statistically associated with otitis media with effusion.

**Conclusion:** Both ears had increased OME and a higher degree of adenoid hypertrophy, indicating the urgent need for therapy and examination of hearing.

**Key Words:** Adenoid Hypertrophy, Impedance Audiometry and otitis media with effusion.

**INTRODUCTION**

An important part of the upper aero-digestive tract's first line of defense is adenoid tissue. "Adenoid" was first used by Wilhelm Meyer to describe what he referred to as "nasopharyngeal vegetations." The adenoid is the topmost segment of Waldeyer's ring, which is a ring of submucosal lymphoid tissues in the pharynx. It is situated behind the choana in the postero-superior wall of the nasopharynx. Between the ages of two and fourteen, adenoids plateau after growing quickly during infancy. They start to regress after the age of 15.<sup>[1]</sup>The most prevalent condition in children,<sup>[2]</sup> is adenoid hypertrophy, which contributes significantly to the pathophysiology of otitis media with effusion,<sup>[3]</sup> and predisposes children to delayed speech and language development as well as poor academic performance.<sup>[4,5]</sup> Adenoids vary in size and reach their maximum size between the ages of three and seven.<sup>[6]</sup> The nasopharyngeal airway narrows as a result of the nasopharynx's soft tissue

growth.<sup>[7]</sup>Then, while the soft tissue stays the same, the nasopharynx grows larger.<sup>[8]</sup> With oedema and blockage of the nasopharyngeal end of the Eustachian tube, chronically infected adenoids serve as a reservoir for upper respiratory infections.<sup>[9,10]</sup> Due to air absorption, enlarged adenoids cause the Eustachian Tube to become blocked, which lowers intratympanic pressure.<sup>[11]</sup> Chronic infection causes connective tissue fibrosis and adenoid tissue epithelial metaplasia, which impair Cilia's ability to function.<sup>[12]</sup>Following exposure to allergens, adenoid tissues exhibit an increase in mast cells and allergic mediators, which bind with immunoglobulin-E (IgE) and release histamines and other inflammatory mediators.<sup>[13]</sup> The mediators that are released alter the structure and function of the cilia and raise the secretory activity of the middle ear mucosal cells.<sup>[14]</sup> The most significant contributing component to the pathophysiology of otitis media with effusion is Eustachian tube dysfunction.<sup>[15]</sup> When ET is blocked, middle ear pressure rises, and adenoid infection-induced bacterial and viral

infiltration from the nasopharynx results in inflammation, mucosal oedema, and increased secretory activity of the middle ear mucosa, which forms an effusion.<sup>[16]</sup> Our aim was to evaluate the impedance audiometric results in children with adenoid hypertrophy critically.

## MATERIALS AND METHODS

This present study was carried out in the Department of ENT, LLRM Medical College, Meerut during the period from November, 2021 to July, 2024. 131 cases of Adenoid hypertrophy were seen with in the study period. They were all with age of 1 to 12 years. All novel instances with adenoid hypertrophy's radiological and clinical characteristics are included. Patients having a history of adenoidectomy, cerebral palsy, ear discharge, cleft palate, or congenital ear deformity are excluded. Our institution granted ethical clearance, and all patients underwent a thorough ENT evaluation, with informed consent obtained from their parents or guardians. As suggested by Fajioke et al,<sup>[17]</sup>only new patients with characteristics suggestive of enlarged adenoids on plain radiographs of the post-nasal area had their adenoid nasopharyngeal ratio (ANR) evaluated and graded using the Sade technique (grade 0, I, II, III).<sup>[18]</sup> In both ears tympanometry was done separately. Performa was used to gather the data, and SPSS version 18 was used to analyze it. The data was deemed significant, and a 95% confidence interval was established.

## RESULTS

During the study period, 131 cases of adenoid hypertrophy were observed. All of them were

between the ages of five and twelve. Males made up the majority (M:F=1.3:1). [Table 1 & Figure1]

According to Table 2 & fig.2, shows the incidence of type B tympanograms was 29.77% and type C tympanograms were 25.95%. 55.72% of people had otitis media with effusion [Table 3]. According to Table 4, patients with grade 3 adenoid hypertrophy appeared to be statistically associated with otitis media with effusion.

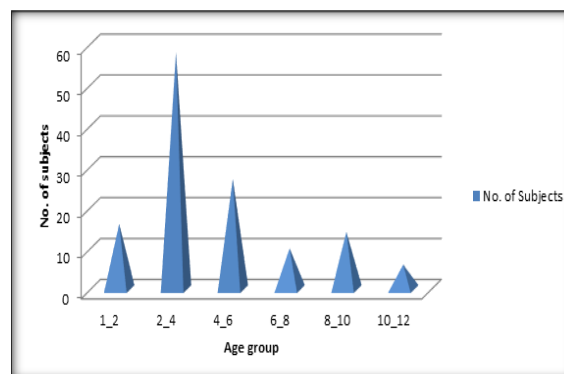


Figure 1: Shows the distribution of subject's a/c age group

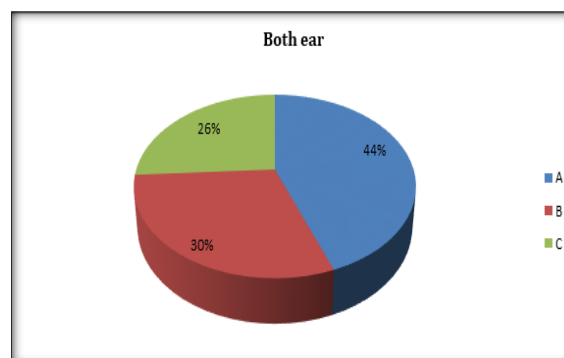


Figure 2: Shows the tympanometric findings in the patients with adenoid hypertrophy.

Table 1: Shows the distribution of subjects a/c age group

Age group in years	No. of Subject (N=131) (%)
1-2	16 (12.2%)
2-4	58 (44.27%)
4-6	27 (20.61%)
6-8	10 (7.63%)
8-10	14 (10.7%)
10-12	6 (4.6%)

Table 2: Shows the tympanometric findings in the patients with adenoid hypertrophy

Tympanometry	Left ear Frequency (%)	Right ear Frequency (%)	Both ear Frequency (%)
A	62 (47.32%)	54 (41.42%)	116 (44.27%)
B	24 (18.32%)	53 (40.45%)	78 (29.77%)
C	45 (34.35%)	24 (18.32%)	68 (25.95%)
Total	131 (100.0%)	131 (100.0%)	262 (100.0%)

Table 3: Shows the incidence of Otitis Media with Effusion

Otitis Media with effusion (OME)	No. of cases (%)
OME	146 (55.72%)
No OME	116 (44.27%)
Total	262 (100.0%)

**Table 4: Shows the association between Otitis Media and Grade 3 adenoid hypertrophy**

Variables	Adenoid Grade 3		P-value
	Yes	No	
OME	92	16	0.04
No OME	20	52	
Total	112	68	

## DISCUSSION

Patients with adenoid hypertrophy had a 55.72% incidence of otitis medium with effusion, with a higher percentage of type B (29.77%) tympanograms than type C (25.95%). The importance of adenoid hypertrophy as a risk factor in the pathophysiology of otitis medium with effusion is thus established. This is comparable to the results that Orji et al. reported in Enugu.<sup>[19]</sup> Using both type B and type C as indicators, a similar study was conducted at Kenyatta National Hospital among children ages 1 to 4 who had adenoid hypertrophy in an outpatient clinic. The prevalence was 67.3%.<sup>[20]</sup> In this study, the proportion of type B tympanograms was higher than that of type C. It indicates that in patients with adenoid enlargement, middle ear effusion is more common than ET dysfunction, resulting in profound hearing loss.<sup>[21]</sup> The results were comparable to those in Kenya, where Type B tympanograms were more common than Type C. Compared to unilateral instances, bilateral cases with otitis media with effusion were more common. Patients with adenoid hypertrophy are more likely to experience a sequence of otitis media with effusion linked to hearing impairment, as bilateral cases typically result in greater hearing impairment than unilateral ones. 56% of patients exhibited grade 3 adenoid hypertrophy, and all children had an adenoid nasopharyngeal ratio. In contrast to previous grades of adenoid hypertrophy, this study demonstrated a strong correlation between grade-3 adenoid hypertrophy and otitis medium with effusion. This implies or demonstrates that in patients with adenoid hypertrophy, an increasing grade of adenoid hypertrophy is a significant predictor of the development of otitis medium with effusion. Even if various methods, including indirect mirror inspection, palpation, endoscopy, etc., have been suggested for diagnosing adenoid hypertrophy, plain radiograph evaluation of the postnasal space of children with characteristics of the condition was nonetheless done on a regular basis. There are currently no thorough recommendations for evaluating adenoidal enlargement, and the relevance of each diagnostic approach is still up for debate.

## CONCLUSION

Our study concludes that patients with adenoid hypertrophy had a high frequency of otitis medium with effusion, with type B tympanograms being more prevalent. An major risk factor for otitis media with effusion in children is the severity of adenoid hypertrophy, which was statistically significant in

cases of bilateral otitis media with effusion compared to unilateral cases.

## REFERENCES

1. Faris C: Scott-Brown's Otorhinolaryngology, Head and Neck Surgery, 7th edn. Ann R Coll Surg Engl. 2011, 93:559.
2. C. D. Bluestone, "Obstructive adenoids in relation to otitis media," *Annals of Otolaryngology, Rhinology and Laryngology*, vol. 84, no. 19, pp. 44–48, 1975.
3. H. Yasan, H. Dogru, and M. Tuz, "Otitis media with effusion and histopathologic properties of adenoid tissue," *International Journal of Pediatric Otorhinolaryngology*, vol. 67, no. 11, pp. 1179–1183, 2003.
4. S. I. Pelton, "New concepts in the pathophysiology and management of middle ear disease in childhood," *Drugs*, vol. 52, supplement 2, pp. 62–67, 1996.
5. J. E. Roberts, M. R. Burchinal, S. C. Jackson et al., "Otitis media in early childhood in relation to preschool language and school readiness skills among African American children," *Pediatrics*, vol. 106, no. 4, pp. 725–735, 2000.
6. M. Jalisi and B. Jazbi, "Chronic middle ear effusion. Current problems in otorhinolaryngology," *Pakistan Doctors Publication*, 85–97, 1991.
7. K. Acharya, C. L. Bhusal, and R. P. Guragain, "Endoscopic grading of adenoid in otitis media with effusion," *Journal of the Nepal Medical Association*, vol. 49, no. 1, pp. 47–51, 2010.
8. W. D. Jeans, D. C. J. Fernando, A. R. Maw, and B. C. Leighton, "A longitudinal study of the growth of the nasopharynx and its contents in normal children," *British Journal of Radiology*, vol. 54, no. 638, pp. 117–121, 1981.
9. K. Tomonaga, Y. Kurono, T. Chaen, and G. Mogi, "Adenoids and otitis media with effusion: nasopharyngeal flora," *American Journal of Otolaryngology—Head and Neck Medicine and Surgery*, vol. 10, no. 3, pp. 204–207, 1989.
10. P. L. Dhingra, "Eustachian tube and its disorders," in *Disease of the Ear Nose and Throat*, pp. 59–60, Gopsons, New Delhi, India, 4th edition, 2009.
11. R. Di Francesco, B. Paulucci, C. Nery, and R. F. Bento, "Craniofacial morphology and otitis media with effusion in children," *International Journal of Pediatric Otorhinolaryngology*, vol. 72, no. 8, pp. 1151–1158, 2008.
12. M. M. Kiroğlu, K. Özbilgin, B. Aydoğan et al., "Adenoids and otitis media with effusion: a morphological study," *American Journal of Otolaryngology—Head and Neck Medicine and Surgery*, vol. 19, no. 4, pp. 244–250, 1998.
13. G. Berger and D. Ophir, "Possible role of adenoid mast cells in the pathogenesis of secretory otitis media," *Annals of Otolaryngology, Rhinology and Laryngology*, vol. 103, no. 8, pp. 632–635, 1994.
14. D. Passali, G. C. Passali, M. Lauriello, A. Romano, L. Bellussi, and F. M. Passali, "Nasal allergy and Otitis media: a real correlation?" *Sultan Qaboos University Medical Journal*, vol. 14, no. 1, pp. e59–e64, 2014.
15. Z. Xia, Z. Wang, L. Cui, C. Wei, Y. Liu, and F. Huang, "The observational and analysis of the function and morphology of the ET in OME and chronic rhinosinusitis in children," *Lin Chung Er Bi Yan Hou Tou Jing WaiKeZaZhi*, vol. 28, no. 13, pp. 929–931, 2014.
16. A. K. Margaret and D. L. Adriane, "Epidemiology of otitis media with effusion," in *Head and Neck Surgery-Otolaryngology*, J. B. Byron, T. J. Jonas, D. N. Shawn, et al., Eds., vol. 1, pp. 1297–1306, Williams and Wilkins, New York, NY, USA, 4th edition, 2006.

17. M. Fujioka, L. W. Young, and B. R. Girdany, "Radiographic evaluation of adenoidal size in children: adenoidal-nasopharyngeal ratio," *American Journal of Roentgenology*, vol. 133, no. 3, pp. 401–404, 1979.
18. J. Sade, *Secretory Otitis Media and Its Sequel*, Churchill Livingstone, New York, NY, USA, 1979.
19. F. T. Orji, N. E. Okolugbo, and B. C. Ezeanolue, "The role of adenoidal obstruction in the pathogenesis of otitis media with effusion in Nigerian children," *Nigerian Journal of Medicine*, vol. 19, no. 1, pp. 62–68, 2010.
20. K. A. Mwaniki, Prevalence of otitis media with effusion in children with obstructive adenoid tissue compared with normal control at the Kenyatta National Hospital. A dissertation in partial fulfillment of the requirement for the degree of masters of medicine at the university of Nairobi, Kenya [M.S. thesis], University of Nairobi, Nairobi, Kenya, 2015.
21. Y. Li, L. L. Hunter, R. H. Margolis et al., "Prospective study of tympanic membrane retraction, hearing loss, and multifrequency tympanometry," *Otolaryngology—Head and Neck Surgery*, vol. 121, no. 5, pp. 514–522, 1999.